



ESENTING CLINICAL SIGNS

History: Recheck degenerative valve disease. No current cardiac medications.

DATE

11/16/22

ECHOCARDIOGRAPHIC FINDINGS

2D, M-mode, and Doppler study. This exam is compared to the one performed 10/29/21.

PERFORMED BY:

Kelly Vazquez

INTERPRETED BY

Keith Blass, DVM,
MS, DACVIM
(Cardiology)

There is mild left atrial dilation. The mitral valve leaflets are mildly thickened, and a moderate jet of eccentric mitral regurgitation is present. There is borderline mild left ventricular dilation. Left ventricular systolic function is mildly hyperdynamic. The aorta and aortic valve are normal. Right atrial and right ventricular dimensions are normal. The tricuspid valve appears normal, though trace tricuspid regurgitation is present. The pulmonary artery and pulmonic valve appear normal, though trace pulmonic insufficiency is present. No shunting lesions are visualized. No pericardial effusion or cardiac masses are seen.

PATIENT

Meisha Benson

LA - 48.4 mm (prev. 43.0 mm)
LVIDd - 42.7 mm (prev. 40.2 mm)
LVIDs - 24.7 mm (prev. 22.6 mm)
FS - 42% (prev. 43.8%)
RA - 28.9 mm (prev. 30.5 mm)
LVOT - 1.32 m/s (prev. 1.68 m/s)
RVOT - 1.00 m/s (prev. 1.18 m/s)

SPECIES

Canine

ASSESSMENT/RECOMMENDATIONS

Degenerative mitral valve disease

This examination demonstrates some progression of Meisha's mitral valve disease over the past year, as she now has mild dilation of her left atrium and moderate dilation of her left ventricle.

BREED

Doberman Pinscher

Meisha's mitral valve disease still appears to be well-compensated, however, her risk for the development of clinical signs secondary to it, such as coughing, exercise intolerance, syncope, and labored breathing, has increased a bit, and careful monitoring for these signs is recommended.

I recommend starting Meisha on pimobendan (7.5 mg am, 5 mg pm), as this medication should help to slow the progression of her mitral valve disease.

SEX

FS

A recheck echocardiogram is recommended in 9 months. Thoracic radiographs are recommended if Meisha experiences respiratory clinical signs.

AGE

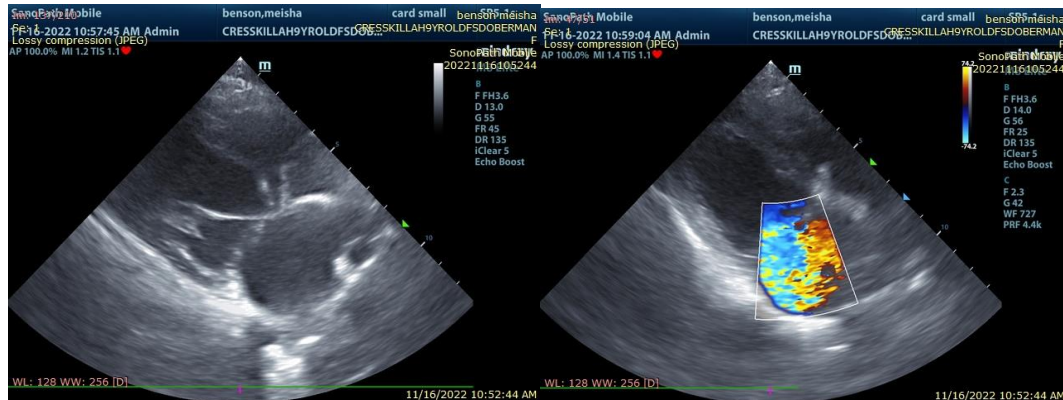
9 y

WEIGHT

51.6 lb

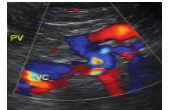
HOSPITAL NAME

Cresskill AH



REFERRING VET

Dr. Khodari



The information and recommendations provided are based on the images presented by the referring veterinarian. No evaluation can be communicated regarding pathology that was not visible in the image/video clips provided.

DATE

11/16/22

Thank you for this referral. If the clinical or image interpretation does not parallel your findings or if I can be of any further assistance please contact me.

PERFORMED BY:

Kelly Vazquez

Keith Blass, DVM, MS, DACVIM (Cardiology)
KeithBlass@gmail.com
631-804-5754

INTERPRETED BY

Keith Blass, DVM,
MS, DACVIM
(Cardiology)

PATIENT

Meisha Benson

SPECIES

Canine

BREED

Doberman Pinscher

SEX

FS

AGE

9 y

WEIGHT

51.6 lb

HOSPITAL NAME

Cresskill AH

REFERRING VET

Dr. Khodari